

Clinical Guideline

Suspected appendicitis

 This guideline should not replace clinical judgment.

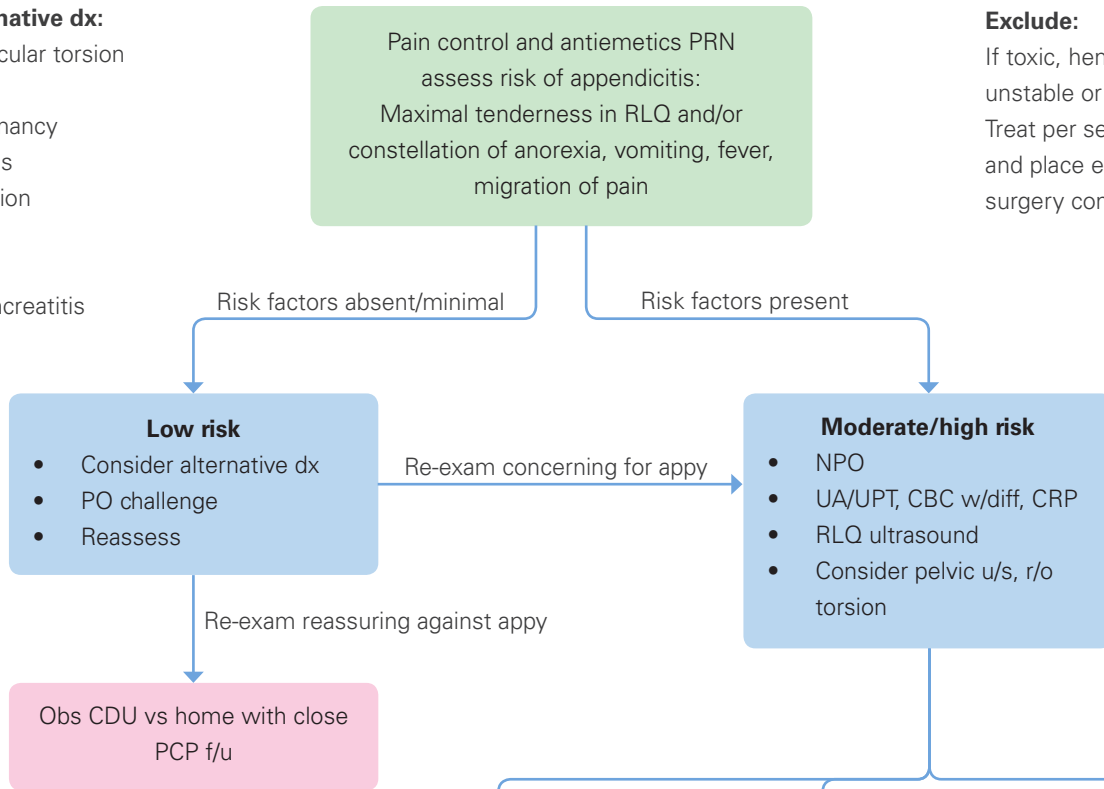
Pediatric Emergency Medicine

Consider alternative dx:

- Ovarian/testicular torsion
- PID
- Ectopic pregnancy
- Pyelonephritis
- Intussusception
- Obstruction
- Meckels
- Hepatitis/pancreatitis
- Viral process

Exclude:

If toxic, hemodynamically unstable or rigid abdomen. Treat per sepsis guideline and place emergent peds surgery consult.



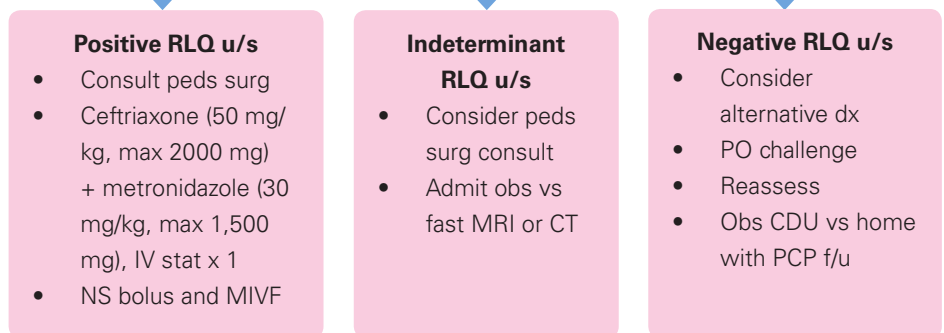
The Pediatric Appendicitis Score

Item	Score (point)
Anorexia	1
Nausea or vomiting	1
Migration of pain	1
Fever >38°C (100.5°F)	1
Pain with cough, percussion or hopping	2
Right lower quadrant tenderness	2
White blood cell count >10,000 cells/microL	1
Neutrophils plus band forms >7,500 cells/microL	1
Total	10 points

Low risk <4, Moderate/high risk ≥4

C: Centigrade; F: Fahrenheit

Data from: Samuel, M. Pediatric appendicitis score. J Pediatr Surg 2002; 37:877.



Suspected Appendicitis Guideline

Executive Summary

Children's Hospital of Richmond at VCU Pediatric Suspected Appendicitis Workgroup

Pediatric Emergency Medicine Owner: Jonathan Silverman, MD, MPH

Pediatric Surgery Owner: Laura Boomer, MD

Pediatric Emergency Medicine: Judy Barto, MD

Pediatric Radiology: Joo Cho, MD

Pediatric Emergency Nursing: Kelly Strickler, RN

Approved (May 2020)

Pediatric Emergency Medicine Quality Committee:

Rashida Woods, MD

Chief of Pediatric Emergency Medicine:

Frank Petruzella, MD, MS

Chief of Pediatric Surgery:

Charles Bagwell, MD

Chief of Pediatric Radiology:

Jacqueline Urbine, MD

CHoR Clinical Guidelines Committee:

Jonathan Silverman, MD, MPH

Ashlie Tseng, MD

CHoR Quality Committee:

José Muñoz, MD

Dory Walczak, MS, RN, NE-BC, CPHQ

References

Duke E, Kalb B, Arif-Tiwari H, Daye ZJ, Gilbertson-Dahdal D, Keim SM, Martin DR. A Systematic Review and Meta-Analysis of Diagnostic Performance of MRI for Evaluation of Acute Appendicitis. *AJR Am J Roentgenol*. 2016 Mar;206(3):508-17.

Krishnamoorthi R, Ramarajan N, Wang NE, Newman B, Rubesova E, Mueller CM, Barth RA. Effectiveness of a staged US and CT protocol for the diagnosis of pediatric appendicitis: reducing radiation exposure in the age of ALARA. *Radiology*. 2011 Apr;259(1):231-9. Epub 2011 Jan 28.

Right lower quadrant pain - suspected appendicitis. Variant 4: Fever, leukocytosis, possible appendicitis, atypical presentation in children (younger than age 14). *ACR Appropriateness Criteria*. American College of Radiology (ACR), 2013. <http://www.acr.org/~media/ACR/Documents/AppCriteria/Diagnostic/RightLowerQuadrantPainSuspectedAppendicitis.pdf>

Zúñiga RV, Arribas JL, Montes SP, Fernandez MN, Abad CG, Martin LG, González-Sagrado M. Application of Pediatric Appendicitis Score on the emergency department of a secondary level hospital. *Pediatr Emerg Care*. 2012 Jun;28(6):489-92.

Citation

Title: **Pediatric ED Suspected Appendicitis Guideline**

Authors:

Children's Hospital of Richmond at VCU

Jonathan Silverman, MD, MPH

Laura Boomer, MD

Judy Barto, MD

Joo Cho, MD

Kelly Strickler, RN

Date: **May 2020**

Retrieval website: <http://www.chrichmond.org/clinical-guideline-suspected-appendicitis>

Example:

Children's Hospital of Richmond at VCU, Silverman J, Boomer L, Barto J, Cho J, Strickler K. Pediatric ED Suspected Appendicitis Guideline. Available from: <http://www.chrichmond.org/clinical-guideline-suspected-appendicitis>